LUMBRICAL TEARS IN ROCK CLIMBERS

A. SCHWEIZER

From the Orthopaedic Department, University Children's Hospital Basel, UKBB, Basel, Switzerland

Performance rock climbing places high demands on the hand and may lead to specific injuries. In a "one-finger-pocket" hold, the interphalangeal joints remain in 20–40° flexion. To increase the maximum force of the holding finger by the quadriga effect, the interphalangeal joints of the adjacent fingers become almost maximally flexed. Holding a "one-finger-pocket" with the ring or small finger leads to a shift of the deep flexor tendons which increases the distance between the two adjacent origins of either the third or the fourth lumbrical. This may cause disruption and tear of that muscle. An organized haematoma in the third lumbrical was visible by ultrasonography in one of the three cases described.

Journal of Hand Surgery (British and European Volume, 2003) 28B: 2: 187–189

INTRODUCTION

The performance as well as the numbers of rock and artificial wall sport climbers have substantially increased in the last 20 years. The top of the open grading scale for the difficulty of a climbing route is at present 11+ (Scale of Union Internationale des Associations d'Alpinisme, UIAA) and many professional climbers compete in an official world cup in several disciplines. Here the whole body weight has to be held on small ledges of only a few millimetres depth or on "one-finger-pockets" big enough only for the distal half of the distal phalanx of one finger (Shea et al., 1992). Therefore, different exercise methods have been developed to increase maximum strength. During eccentric plyometric training, the climber hangs and jumps from grip to grip, upwards and downwards, without support of the feet. Furthermore, a method where single fingers are trained separately has been described to improve the overall maximum strength of the finger flexors in already highly trained athletes (Köstermeyer and Weineck, 1995). Such specialized exercise methods and competitions are leading increasingly (Holtzhausen and Noakes, 1996) to very specific injuries of the fingers and hand (Bannister and Foster, 1986; Bollen, 1990) such as the A2 pulley disruption (Moutet et al., 1993; Rohrbough et al., 2000), an injury which does not occur in other sports or activities (Bollen, 1988). Many injury patterns like the A2 pulley rupture (Rohrbough et al., 2000) and the injury caused by a lumbrical shear remained unrecognized because they did not substantially interfere with the function of rock climbing.

CASE REPORTS

Three ambitious recreational rock climbers, all men aged 25–29 years (UIAA level: 9–10+) were seen with the same unique injury mechanism and symptoms. During the hold of a one-finger-pocket with the ring finger where the distal phalanx was loaded at between 300 and 400 N (Fig 1), a sudden audible snap occurred in two cases in the palm followed by pain along the flexor tendons. The third case had no snap but after repeating a single hard climbing move with the ring

Fig 1 Holding a one-finger-pocket with the typical position of the interphalangeal joints, where the loaded finger is nearly extended and the adjacent fingers are flexed almost maximally to increase maximum strength by the quadriga effect.

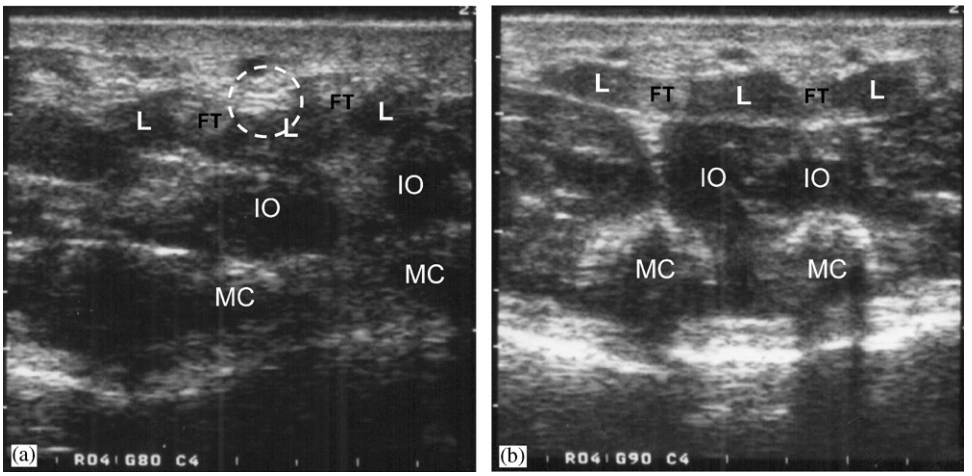

Fig 2 (a) Ultrasound taken 10 days after injury showing an enhancement in the third lumbrical next to the flexor tendons in the proximal part of the palm corresponding to an organized haematoma (dashed circle). (b) Ultrasound taken 4 years after injury showing normal lumbricals with almost equal diameters (L: lumbricals; FT: flexor tendons; IO: interossei; MC: metacarpal bones).

finger experienced severe pain and swelling in the finger and the palm. In all cases, the ring finger (two left, one right) was involved. Neither the function of the flexor tendons was impaired nor were there signs of a pulley rupture. A painful area over the flexor tendons of the ring and middle fingers in the palm was found. Holding a one-finger-pocket with the involved finger caused a sharp pain in the palm whereas holding a two-finger-pocket with the ring and middle finger together, or holding a ledge (interphalangeal joints of all fingers in the same degree of flexion) was painless even at high load. On the assumption that the two origins of the fourth lumbrical had been torn apart and disrupted, the athletes were advised to avoid holding one-finger-pockets, but were allowed to train further as long as the middle and ring finger were loaded together and in similar joint angle positions. They were advised to apply a buddy taping enclosing the middle and ring finger. A moderate stretching programme was advocated in which the middle finger was forced into a flexed position and the ring finger into an extended position and vice versa. The pain disappeared after 6–10 weeks. Exercises on one-finger-pockets were started after 2–4 months. Two of the climbers did not reach the same maximum strength as before the injury and still have a strange insecure feeling when pulling on a one-finger-pocket 3 and 4 years after injury. The other is still in the rehabilitation phase but had improved substantially after 4 weeks. An ultrasound examination was performed 10 days after his injury and one of the other climbers was scanned 4 years after injury. The acute injury showed an enhancement in the third lumbrical next to the flexor tendons in the proximal part of the palm, corresponding to an organized haematoma whereas the older injury showed a normal lumbrical with a similar diameter compared to the other lumbricals (Fig 2).

DISCUSSION

So far there have been only few reports of injuries to the lumbricals. Watson (Watson et al., 1974) described post-traumatic interosseous-lumbrical adhesions causing symptoms which were relieved by release and resection. Two studies (Murphy and Calandruccio, 1996; Murphy and Chernofsky, 1999) have reported a rupture of the lumbrical, which was due to an anomalous origin of that muscle in one case. The unique injury described here is the result of a specific high load and occurred exclusively in rock climbers because of the specific anatomy of that muscle. The third lumbrical has a two-tailed origin from the third and fourth deep flexor tendons. The bipennate shape of its muscle belly may be the reason for this specific injury as rock climbers usually hold one-finger-pockets with the middle or ring finger because of the greater strength (Schweizer, 2001). During the hold of a one-finger-pocket (Fig 1), the proximal interphalangeal joint is flexed about 10–20° and the distal interphalangeal joint about 40°. The interphalangeal joints of the adjacent fingers become almost maximally flexed, increasing the maximum force of the holding finger up to 48% (Schweizer, 2001) by the quadriga effect of the flexor digitorum profundus muscle (Verdan and Poulenas, 1975). This results in a shift of the deep flexor tendons against one another and increases the distance between the adjacent origins of the third lumbrical, causing disruption or tear of that muscle (Fig 3). The pain after such an injury can be elicited by repeating

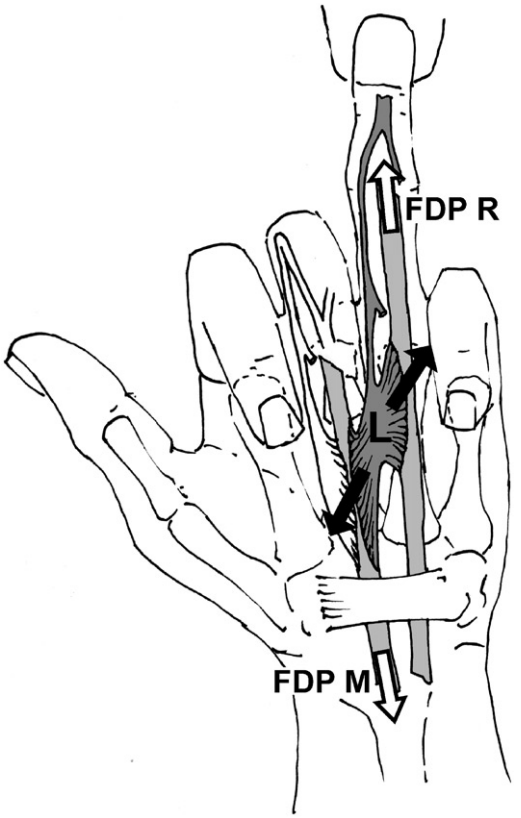

Fig 3 The shift of the deep flexor tendons of the ring (FDP R) and the middle (FDP M) finger during a one-finger-pocket hold increases the distance between the adjacent two origins (black arrows) of the third lumbrical (L). This may cause disruption and tear of this muscle.

the same manoeuvre and can be avoided by holding a two- or more finger-pocket or a ledge where the flexor profundus tendons of each finger remain in the same relative positions and both origins of the lumbrical lie next to each other. A tear or disruption of a lumbrical can be detected by ultrasound examination. The treatment is to avoid holding one-finger-pockets and to stretch the lumbricals to prevent scar tissue formation. This is performed by actively forming a fist or passively forcing the fingers into the intrinsic minus position in order to stretch the lumbricals (Stack, 1962). Although the same flexibility and strength as before the injury may not be achieved, rock climbing ability is not substantially impaired.

References

Bannister P, Foster P (1986). Upper limb injuries associated with rock climbing. British Journal of Sports Medicine, 20: 55.

Bollen SR (1988). Soft tissue injury in extreme rock climbers. British Journal of Sports Medicine, 22: 145–147.

Bollen SR (1990). Upper limb injuries in elite rock climbers. The Journal of the Royal College of Surgeons of Edinburgh, 35: S18–S20.

Holtzhausen LM, Noakes TD (1996). Elbow, forearm, wrist, and hand injuries among sport rock climbers. Clinical Journal of Sport Medicine, 6: 196–203.

Köstermeyer G, Weineck J (1995). Notwendigkeit des einfingrigen Trainings der Fingerbeugemuskulatur zur Leistungssteigerung im Sportklettern. Vergleich der Kraftentwicklung bei ein- und vierfingriger Maximalkontraktion. Deutsche Zeitschrift für Sportmedizin, 46: 356–362.

Moutet F, Guinard D, Gerard P et al. (1993). Subcutaneous rupture of long finger flexor pulleys in rock climbers. 12 case reports. Annales de Chirurgie de la Main et du Membre Superieur, 12: 182–188.

Murphy D, Calandruccio JH (1996). Persistent post-traumatic fourth web space pain after rupture of the fourth lumbrical muscle: a case report. Journal of Hand Surgery, 21A: 249–250.

Murphy RX, Jr., Chernofsky MA (1999). Tear of an anomalous lumbrical muscle as a source of pain in the hand. Journal of Hand Surgery, 24A: 1078–1082.

Rohrbough JT, Mudge MK, Schilling RC (2000). Overuse injuries in the elite rock climber. Medicine and Science in Sports and Exercise, 32: 1369–1372.

Schweizer A (2001). Biomechanical properties of the crimp grip position in rock climbers. Journal of Biomechanics, 34: 217–223.

Shea KG, Shea OF, Meals RA (1992). Manual demands and consequences of rock climbing. Journal of Hand Surgery, 17A: 200–205.

Stack HG (1962). Muscle function in the fingers. Journal of Bone and Joint Surgery, 44B(4): 899–909.

Verdan C, Poulenas I (1975). Anatomic and functional relations between the tendons of the long palmar muscle and the long flexor muscle of the thumb at their crossing in the carpus. Annales de Chirurgie Plastique, 20: 191–196.

Watson HK, Ritland GD, Chung EK (1974). Post-traumatic interosseus-lumbrical adhesions. A cause of pain and disability in the hand. Journal of Bone and Joint Surgery, 56A: 79–84.

Received: 13 May 2002
Accepted: 29 July 2002
Dr med. A. Schweizer, Brittnauerstrasse 8, CH 4800 Zofingen, Switzerland. Tel.: +41 62 752 26 67; E-mail: ankaluz@active.ch.

© 2003 The British Society for Surgery of the Hand. Published by Elsevier Science Ltd. All rights reserved.
doi:10.1016/S0266-7681(02)00250-4/jhsb.2003.0852, available online at http://www.sciencedirect.com